

**Shriners
Hospitals
for Children**

TREATMENT EDUCATION RESEARCH

Springfield, Massachusetts



SAVE THE DATE!

**Eleventh Annual
Bone & Joint Course
for Pediatricians and
Family Physicians**

**Thursday, June 7, 2007
1:00 - 5:30pm
Lunch - Noon**

For information or registration
call Laurie Duffy at
(413) 787-2027 or email
lduffy@shrinenet.org

IN THIS ISSUE:

Use of a 3D
Body Scanner

Medical Library
for Area Pediatricians

Phalanx Fractures
in Children

New Consultants
at Shriners Hospital

TO REFER A PATIENT

For an appointment or
to make a referral call
(413) 735-1234 or
800-322-5905.

New Technology – Use of a 3D Body Scanner for Evaluating Alignment, Balance, Symmetry and Posture in Spine and Trunk Deformities

Peter D. Masso, M.D., Assistant Chief of Staff & Medical Director of the Clinical Outcomes Assessment Laboratory

George E. Gorton, III, Director of Clinical Outcomes Assessment Laboratory

Overview

There is increasing emphasis on patient-based outcomes in medicine to evaluate the efficacy of treatment from the patient's and provider's perspectives. Scoliosis, pectus excavatum, and pectus carinatum affect the appearance of the spine and chest wall. The primary technical outcomes followed by the provider are frequently derived from radiologic measures such as the Cobb Angle for scoliosis, however this has a poor correlation to patient outcomes such as satisfaction and happiness with appearance. The impact of treatment on outcomes related to changes in body shape and patient satisfaction has not been studied. Objective methods of measuring changes in body shape would provide necessary information to assist in treatment planning and outcome assessment.

Shriners Hospitals for Children, Springfield has recently initiated a comprehensive assessment of outcome using new technology to objectively evaluate global and segmental alignment, symmetry, balance, and posture of patients with spinal and chest wall deformities in conjunction with patient response questionnaires and other clinical outcome measures.

Technology

Until recently, it was difficult to measure and describe changes in chest wall deformity over time or as the result of intervention. Quantifying a complex surface shape is technically challenging. Previous methods have included radiographic techniques, moiré topography, rasterstereography, mechanical devices, and photography. All of these have been limited by their inability to measure full body 3D topography and by their accuracy and resolution.

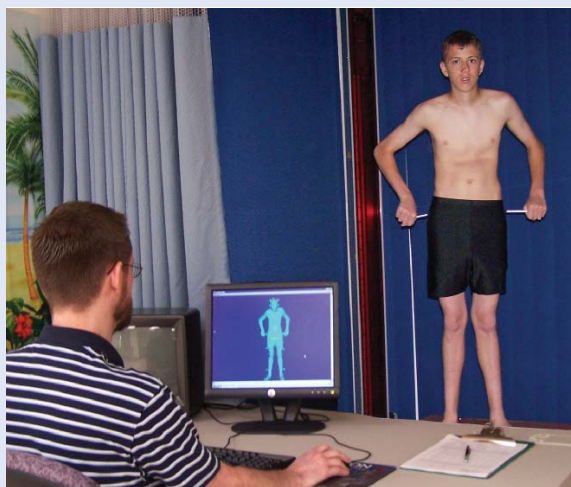


Figure 1. The 3D Body Scanner creates a digital twin in less than 15 seconds on a computer using eye-safe laser light.

3-D body scanning has been previously used in the textile industry to understand and develop improved sizing standards for clothing, as well as to customize sizes on an individual basis. It is now possible to have a custom suit made directly from scan measurements, ensuring a perfect fit. Transfer of this technology to the medical field is taking place as the result of a research partnership between Stryker Spine, Vitronic Machine Vision, Human Solutions of North America and Shriners Hospitals for Children, Springfield.

In April, 2006, Shriners Hospitals for Children, Springfield became the first hospital to begin using 3D body scanner technology to track the posture and chest wall shape of patients with spine and chest wall deformities. In 15 seconds four eye-safe lasers

“The site and magnitude of deformity, as well as the extent of postoperative correction, including residual deformity for individual patients are clearly demonstrated by this technology.”

and eight synchronized cameras scan the body to produce a three-dimensional surface map of approximately 2 million data points with 4 mm resolution (Figures 1-2). This is transformed into a “digital twin” that can be manipulated in 3 dimensions and customized measurements, including distances, circumferences, and angles can be extracted.

Methods

Each adolescent with a spine or chest wall deformity seen in the Clinical Outcomes Assessment Laboratory (formerly the Motion Analysis Laboratory) has a digital twin created using the 3D Body Scanner. A postural assessment using a motion capture system is performed in addition to the standard radiographs and clinical photos, as well as an outcome questionnaire looking at quality of life and satisfaction. Since April, more than 100 adolescents with scoliosis, 50 adolescents with pectus excavatum or carinatum and 20 adolescents without spine or chest wall deformity have been evaluated in this manner. Measures of system accuracy and reliability have been assessed. A global symmetry profile, including measures of shoulder rotation and elevation, anterior and posterior trunk topographical symmetry, lateral offset and sagittal plane contour has been devised. These measures of appearance are being used to visualize and quantify the changes in body shape that occur during treatment and to correlate with other outcome measures.

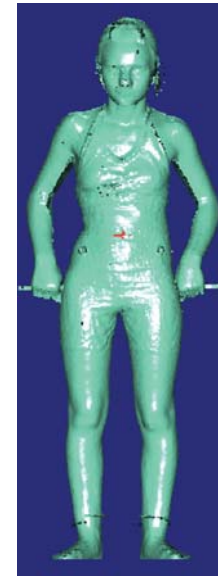

Figure 2. The digital twin is a full three dimensional model of the body topography that can be rotated in any direction and measurements can be made of topographical features, including cross sections and longitudinal sections.

Results

Interobserver reliability of the scanner in determining the distance between landmarks was 1.5mm (+/-1.3mm). Aspects of the global symmetry profile are able to differentiate normal from pathologic and preoperative from postoperative. Figures 3-5 show an adolescent female before and after posterior spinal instrumentation and fusion. The Cobb Angle on the x-ray demonstrates full correction of the spinal deformity. The body scan shows that although the curvature was corrected, and the rotation of the torso is improved, the rib prominence and lateral trunk offset remain. Figure 6 shows an adolescent male before and after Nuss procedure to correct a pectus excavatum. The body scan shows a complete initial correction of the deformity, with some residual changes occurring over time that will be followed observationally. The site and magnitude of deformity, as well as the extent of postoperative correction, including residual deformity for individual patients are clearly demonstrated by this technology.

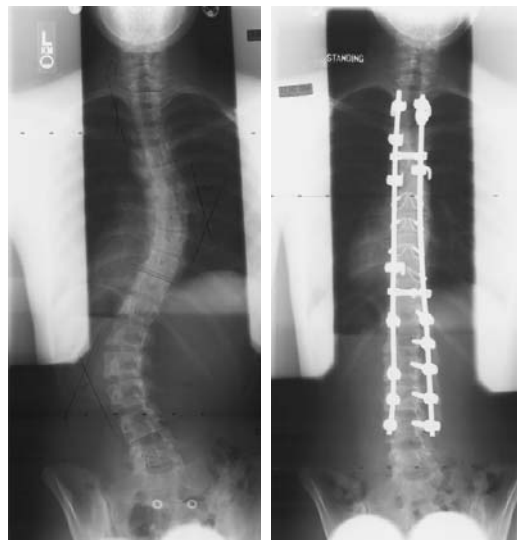


Figure 3. Pre (left) and Postoperative (right) radiographs show good correction of the scoliosis.

Conclusion

Current measures commonly used for the evaluation of spinal deformities and its interventions do not correlate with the resultant trunk global or segmental alignment, balance, and posture of patients or patient satisfaction. Body scanner methodology gives a repeatable, rapid, noninvasive, global and segmental assessment of a patient’s alignment, posture and balance which deserves further study. 3D Body Scanner technology presents a highly promising opportunity to objectively document Process and Patient Outcomes related to chest wall deformity.



Peter D. Masso, M.D.



George Gorton

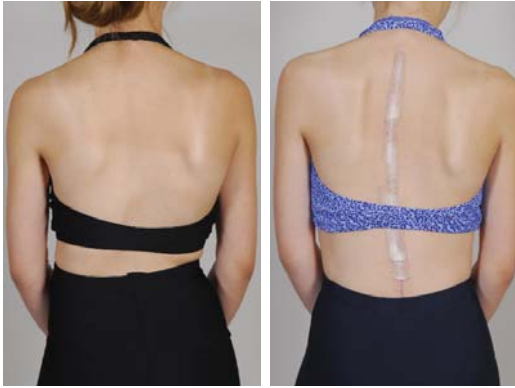

Figure 4. Pre (left) and Postoperative (right) photographs show good correction of the scoliosis.

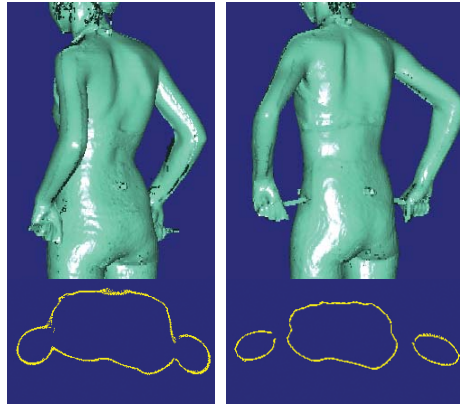


Figure 5. Pre (left) and Postoperative (right) body scans show good correction of shoulder rotation, however the rib and chest wall prominences remain and there is an offset of the trunk to the left.

“Body scanner methodology gives a repeatable, rapid, noninvasive, global and segmental assessment of a patient’s alignment, posture and balance which deserves further study.”




Figure 6. This patient with a pectus excavatum (a concave chest wall deformity) is shown before a Nuss procedure to correct the deformity and one day, 3 months and 4 months following correction. The scanner shows the initial correction to the shape of the chest as well as postoperative changes that are being followed clinically by Dr. Kevin Moriarty.

Kevin P. Moriarty, M.D., has been on the consulting staff at Shriners Hospital for 10 years. Dr. Moriarty conducts a Chest Wall Deformity Clinic in the Hospital’s Outpatient Department and has surgical hours in the operating room. Dr. Moriarty is in private practice with Pediatric Surgical Services, Inc. in Springfield.

Medical Library for Area Pediatricians

Susan LaForte, Director of Library and Online Services

Shriners Hospital for Children has an excellent small medical library specializing in pediatric orthopaedics, rehabilitation therapy, and prosthetics & orthotics. The Hospital subscribes to the major journals in these fields, including *Acta Orthopaedica*; *Clinical Orthopaedics and Related Research*; *The Journal of Hand Surgery*, parts A and B; *The Journal of Pediatric Orthopaedics*, parts A and B; *Clinical Orthopaedics and Related Research*; and *Spine*. The textbook collection reflects a similar commitment to excellence, staying up-to-date and comprehensive.

Because the staff sees and treats so many unusual conditions, the medical library offers several resources on rare disorders and subscribes to the online database of **NORD**, The National Organization of Rare Disorders. NORD prepares reports on hundreds of syndromes, listing signs and symptoms, etiology, standard and investigational therapies, resources, and references.

Area physicians are welcome to make use of the Library. To schedule an appointment, or to request a reprint, or NORD report, please contact Susan LaForte, Director of Library and Online Services at 413-787-2053 or slaforte@shrinenet.org.



Susan LaForte

SHRINERS HOSPITALS FOR CHILDREN

A highly skilled medical staff provides first rate care to 1,000 inpatients and over 26,000 outpatient visits annually. The medical staff is comprised of board certified orthopaedic surgeons who are fellowship trained in pediatric orthopaedics, a pediatrician/pediatric rheumatologist, part-time orthopaedic surgeons, and over 90 consulting physicians and surgeons.

Shriners Hospital maintains teaching affiliations with Boston University School of Medicine and Albany Medical College. Additionally, Shriners Hospital provides training to undergraduates and graduate students from area colleges and universities in the fields of nursing, occupational/physical therapy, prosthetics and orthotics, motion analysis, child life and social services.



SPECIALTY CLINICS

Each weekday children are seen in specialty clinics in the Hospital's Outpatient Department. Specialty clinics are held weekly, bi-monthly or monthly:

- Club Foot
- Developmental Dysplasia of the Hip and Other Hip Disorders
- Legg-Calvé Perthes Disease
- Congenital and Acquired Limb Deficiencies
- Scoliosis and Other Spine Deformities
- Hand Deformities
- Shoulder Deformities
- Osteogenesis Imperfecta
- Juvenile Rheumatoid Arthritis
- Chest Wall Deformities
- Neuromuscular Disorders including Cerebral Palsy
- Myelodysplasia (Spina Bifida)
- Genetic Counseling for Orthopaedic Conditions
- Metabolic Bone Disease
- Cleft Lip and Palate

516 Carew Street
Springfield, MA 01104-2396
TEL: (413) 787-2000
FAX: (413) 787-2054
www.shrinershq.org

Phalanx Fractures in Children

Elaine Charest MA, MBA, OTR/L, Director of Rehabilitation Services
Steven M. Wenner, M.D., Consulting Staff Orthopaedic Surgeon

The child's hand is one of the most frequently injured parts of the growing body. Its frequent use and exposure, especially in athletic activities, coupled with curiosity and lack of natural caution results in a wide array of injuries to the digits. Worlock & Stower, studying an "at-risk" population estimated an annual incidence rate of 26:10,000 for hand fractures.^[1]

Studies have shown the incidence of hand fractures rises after the age of 8 years. This is probably due to more aggressive play and increased participation in sports. More of these fractures occur in boys than in girls. They may take place at home, in the school yard or on the playing field. Specific sports which are hand-intensive and moderately violent, such as football and basketball, are associated with a particularly high incidence of injury.^[2]

Early diagnosis of digital injuries, followed by prompt treatment of them, provides the best chance for an excellent outcome. Many fractures can be treated by splinting or casting alone, or closed reduction and casting. The ability to perform a successful closed reduction is time-dependent. The sooner after the injury it is attempted, the more predictably it can be performed.

Clinical symptoms associated with fracture of a digit typically include local tenderness, swelling, ecchymosis. There may be deformity of a finger (angular or rotational) and diminished range of motion. Radiographs in the anteroposterior, lateral, and oblique planes are essential for diagnosis. At the Shriners Hospital for Children – Springfield, we do not undertake the emergency management of such injuries. Patients so injured should be referred to their local hospital emergency room, or to an orthopedic surgeon.

1. Worlock, P.H. and M.J. Stower, *The incidence and pattern of hand fractures in children*. J Hand Surg [Br], 1986. **11**(2): p. 198-200.
2. Graham, T.H., H, *Fractures and Dislocations in the Child's Hand*, in *The Growing Hand*, K.S. Gupta A, Scheker LR, Editor. 2000, Mosby: London. p. 591-607.

Steven M. Wenner, M.D., has been on the consulting staff at Shriners Hospital for 27 years. He conducts a Hand and Upper Extremity Clinic once a month in the Hospital's Outpatient Department and has surgical hours in the operating room. Dr. Wenner is in private practice with New England Orthopaedic Surgeons in Springfield.



Elaine Charest



Steven M. Wenner, M.D.

New Consultants at Shriners Hospital



Mary-Alice Abbott, M.D., Ph.D., has joined the consulting staff at Shriners Hospital for Children in Springfield. Dr. Abbott is a Clinical Geneticist and will be seeing patients in the Hospital's Cleft Lip and Palate Clinic which is held monthly. Dr. Abbott earned her medical degree and Ph.D. at the University of Massachusetts Medical School and Graduate School of Biomedical Sciences in Worcester. She completed combined residency programs in pediatrics and medical genetics at the University of Connecticut, Connecticut Children's Medical Center in Hartford. Dr. Abbott is board certified in both clinical genetics and pediatrics and is on staff at Baystate Children's Hospital.



Eric T. Tolo, M.D., an orthopaedic surgeon from the Lahey Clinic Medical Center in Burlington and Peabody, Massachusetts has joined the consulting staff at Shriners Hospital. Dr. Tolo is a graduate of Cornell University Medical College. He completed his orthopaedic residency at the Hospital for Special Surgery in New York City. Dr. Tolo went on to complete a hand and microvascular fellowship at the Mayo Clinic in Rochester, Minnesota and later joined the Lahey Clinic as a hand and upper extremity surgeon. His interests include upper extremity reconstruction and arthroscopy. Dr. Tolo will have surgical hours at Shriners Hospital and will see patients in the Upper Extremity Clinic.

For complete copies of abstracts, contact: Laurie Duffy, Medical Staff Services, tel: (413) 787-2027 or e-mail: lduffy@shrinenet.org

Editor: Bernadette A. White, Director Public Relations, tel: (413) 735-1291 or e-mail: bwhite@shrinenet.org