

Lyme Disease and Arthritis

Lawrence Zemel, M.D., *Consulting Staff / Pediatric Rheumatologist*

While the 2001 season for *acute* Lyme disease is coming to a close, *chronic* Lyme disease may occur at any time of the year, months after exposure. The two major systems affected by chronic *Borrelia* infection are musculoskeletal and nervous.


Lyme arthritis typically presents with a single, very swollen knee. Low-grade fever may be present, but most patients are afebrile. There is less pain than expected by the degree of swelling. There is usually a history of spending time in Lyme endemic areas (Cape Cod, Martha's Vineyard, western Massachusetts [recently], and much of the northeast). Only 25-30% of children with Lyme arthritis report prior erythema migrans, the pathognomonic skin marker, since early treatment of Lyme disease usually prevents chronic sequelae.

In a recent retrospective analysis of Lyme arthritis, I found that 90% of children with Lyme arthritis had knee involvement at some time, while hips were involved 14% of the time, ankles 10%, and small joints of the hands were rarely involved. Lyme arthritis was monoarticular in 63% of patients; 37% of children had 2-4 joints involved, episodically. Sedimentation rates were elevated in 77% of cases, with a mean sed rate of 42. Synovial fluid revealed a mean WBC of 38,000, predominantly polys. After nearly 8 years of follow-up of 90 children with Lyme arthritis, none of the patients developed chronic arthritis.

More worrisome than Lyme arthritis is neuroborreliosis, or CNS Lyme disease. This is often heralded acutely by multiple erythema migrans, fever, headaches, and mild neck stiffness. If not treated aggressively at this early stage, acute symptoms

spontaneously remit, but late Lyme encephalopathy may develop months later. Typical features include chronic headaches, episodic neck pain or stiffness, fatigue, and neurocognitive complaints. The latter include short-term memory loss, diminished ability to concentrate ("zoning out"), and significant drop in academic performance. Neuroborreliosis may be associated with intrathecal borrelia antibody production, pseudotumor cerebri, auditory recall deficits on neuropsychological testing, and rarely, MRI abnormalities. Lyme serology is almost always positive in chronic Lyme disease, with at least 5 positive bands on Western blot testing.

Treatment of Lyme arthritis is with oral antibiotics initially, such as one month of amoxicillin or doxycycline, along with non-steroidal anti-inflammatory agents. Intravenous antimicrobial therapy is used for CNS Lyme disease, or resistant Lyme arthritis, for a duration of 3-6 weeks. Typical drugs used include ceftriaxone, cefotaxime, penicillin, or imipenim. Eight of my patients have now undergone arthroscopic synovectomy of the knee because of resistant Lyme arthritis confined to the one joint. Maintaining a high index of suspicion for Lyme disease during the early stages, with prompt treatment, often circumvents the later complications.

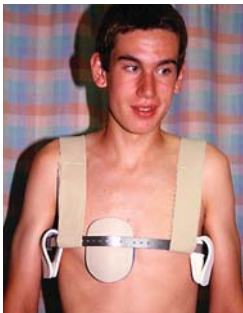


Dr. Lawrence Zemel conducts a Rheumatology Clinic three times a month in Shriners Hospital's Outpatient Department. He is a staff rheumatologist at Connecticut Children's Medical Center in Hartford, CT.

"The two major systems affected by chronic *Borrelia* infection are musculoskeletal and nervous."



Pectus Carinatum Orthosis



Patient wearing orthosis

Custom Orthotic Treatment for Pectus Carinatum

James Athearn, C.O., *Director Orthotics & Prosthetics Laboratory* • Kim Gettens, *Certified Orthotist*
Kevin P. Moriarty, M.D. • Stanley Konefal, Jr., M.D.

From September of 1999 through May 2001, our Prosthetic and Orthotic Department had 12 patients with the diagnosis of Pectus Carinatum referred to us for orthotic treatment. We have developed a custom orthotic system to reduce the chest wall prominence associated with Pectus Carinatum via application of external pressure; this is a modification of previously designed orthoses. It is important to explore the possibility of orthotic treatment, as there is no minimally invasive surgery to correct this deformity.

Only patients who reported compliance with orthosis wear and were at least one year into the orthotic regimen were considered for review. Four patients were non-compliant and four were less than one-year into the program. The remaining four patients who fulfilled the criteria are reviewed.

All patients had baseline computed tomography (CT) scans obtained. The four patients who fulfilled the criteria had follow-up CT scans after approximately one-year of brace treatment (Range: 10 months to 16 months). Utilizing a method of measuring sternal rotation, objective measurements of the pre-bracing deformity were compared to the residual deformity present after orthotic intervention.

All four patients had visible signs of improvement per chart review at six months. At one year, CT scans were reviewed, with three of the four patients displaying improvement of their deformity. Review of one negative result indicated that the patient had decreased wearing the orthosis below the recommended wear time, after seeing the initial six-month improvement. We are continuing to monitor the remainder of the patients in the Pectus Carinatum Orthoses. jathearn@shrinenet.org

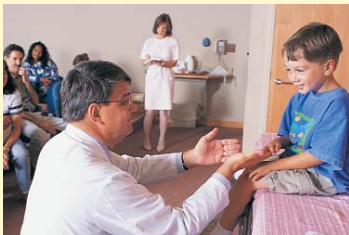Topic presented at the 10th World Congress of the International Society for Prosthetics and Orthotics in Glasgow, Scotland, UK, July 5, 2001.

Kevin P. Moriarty, M.D. and Stanley Konefal, Jr., M.D., pediatric surgeons on Shriners Hospital's consulting staff, conduct a Pediatric Surgery Clinic once a month in the Outpatient Department.

SHRINERS HOSPITALS FOR CHILDREN

Shriners Hospital in Springfield, Massachusetts is a 40 bed pediatric orthopaedic hospital licensed by the State of Massachusetts and accredited by the Joint Commission on Accreditation of Healthcare Organizations.

Our Hospital provides treatment for diseases of the bones, muscles and joints to children from birth to 18 years of age. All care, while at Shriners Hospital, is provided at no charge to patients, families, insurance companies or governmental agencies.



HOW TO MAKE A PATIENT REFERRAL

Any child with orthopaedic needs is eligible for care at Shriners Hospitals regardless of race, religion, national origin, financial status, or insurance coverage. The child must be under the age of 18, have an orthopaedic need that can be treated by our staff, and a completed hospital application. There is no need to have an affiliation with a Shriner or be related to one.

- Patients and families may contact the hospital directly by calling 413-787-2070 or 800-322-5905.
- Physicians may refer patients directly to the Chief of Staff at 413-787-2058.

IN THIS ISSUE:

Latex Allergy in Children
Lyme Disease and Arthritis
Custom Orthotic Treatment
for Pectus Carinatum

Physeal Injuries of
the Distal Phalanx

The Use of Botulinum Toxin A
Compared to Serial Casting
in the Treatment of Children
with Cerebral Palsy

Cleft Lip and Palate Clinic

Cleft Lip and Palate Clinic

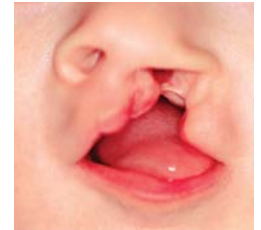Philip B. Stoddard, M.D., *Consulting Staff / Plastic & Reconstructive Surgery*

The Cleft Lip and Palate Clinic at the Shriners Hospital for Children in Springfield is completing its third full year of service in this location. The professional and support staff, patients and families are enthusiastic about the support that Shriners provides for the Cleft Lip and Palate Program.

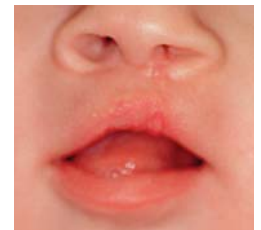Cleft lip and palate remains the fourth most common congenital birth abnormality occurring about 1 in 700 live births. At the clinic we evaluate, treat and follow 15 to 20 patients every month. The cleft lips are repaired at about three months of age, or later if an orthodontic appliance needs to be used to narrow the gap prior to repair. Newborns often have feeding problems that are addressed by our therapists and nutritionist. The cleft palate is repaired 12 to 18 months of age, and most children with cleft palate need middle ear drainage because of eustachian tube dysfunction and repeated middle ear infections. Children with cleft palate are at risk for speech and learning disorders and screening is done on an on-going basis.

The team approach to caring for these children include specialists from plastic surgery, otolaryngology, orthodontics, oral and maxillo-facial surgery, speech language pathology, nursing, occupational therapy, nutrition and social work. The Shriners organization has been most supportive in sponsoring this multi disciplinary service for those children born with cleft lip and palate.

Dr. Philip B. Stoddard is the Director of the Cleft Lip and Palate Clinic which is conducted once a month in Shriners Hospital's Outpatient Department. He is also in private practice, and an attending physician at Baystate, Mercy and Providence Hospitals, and on the consulting staff at Holyoke Hospital.



Before surgery



After initial surgery

Each weekday children are seen in specialty clinics in the Hospital's Outpatient Department. Specialty clinics are held weekly, bi-monthly or monthly:

- Club Foot
- Development Dysplasia of the Hip and other Hip Disorders
- Legg-Calvé-Perthes Disease
- Congenital and Acquired Limb Deficiencies
- Scoliosis and other Spine Deformities
- Hand and Shoulder Deformities
- Juvenile Rheumatoid Arthritis
- Cleft Lip/Palate
- Neuromuscular Disorders including Cerebral Palsy
- Myelodysplasia (Spina Bifida)
- Genetic Counseling for Orthopaedic Conditions
- Metabolic Bone Disease
- Pediatric Surgical Clinic including Chest Wall Deformities

For complete copies of abstracts, contact: Linda Nahorniak, Medical Staff Services, tel: (413) 787-2058 or e-mail: lnahorniak@shrinenet.org

Editor: Bernadette A. White, Director Public Relations, tel: (413) 735-1291 or e-mail: bwhite@shrinenet.org



Shriners Hospital for Children
516 Carew Street
Springfield, MA 01104-2396

RETURN SERVICE REQUESTED

NONPROFIT ORG.
U.S. POSTAGE
PAID
Springfield, MA
Permit No. 1177