



Ductal carcinoma in situ in a 16-year-old adolescent boy with gynecomastia: a case report

George M. Wadie*, Gregory T. Banever, Kevin P. Moriarty,
Richard A. Courtney, Theonia Boyd

*Divisions of Pediatric Surgery and Pathology, Baystate Medical Center Children's Hospital,
Tufts University School of Medicine, Springfield, MA 01199, USA*

Index words:

Ductal carcinoma in situ
(DCIS);
Gynecomastia;
Male

Abstract Ductal carcinoma in situ (DCIS) of the male breast is rare. Even more rare is the finding of DCIS in association with gynecomastia. After an extensive literature search, only two cases have been reported in the literature, both in adults. Here we present the case of a 16-year-old adolescent boy who presented with pubertal gynecomastia that was treated with bilateral subcutaneous mastectomies. A DCIS focus was found in the right breast specimen, and the patient underwent bilateral completion total mastectomies uneventfully. Despite its rarity, surgeons should be aware of the possibility of the breast of adolescents with gynecomastia harboring a neoplastic focus.

© 2005 Elsevier Inc. All rights reserved.

Gynecomastia, the Greek term for the presence of female-type mammary glands in the male, is a common disorder in pubertal boys [1]. Usually considered a cosmetic problem, its true incidence is not known [2], with reports in the literature ranging between 60% and 70% [3,4]. There is a significant discrepancy regarding the association of this disorder with breast cancer in males [2]. Clinical gynecomastia has rarely been associated with breast cancer [5,6], and most authors failed to find convincing evidence associating the 2 conditions [7,8]. A more rarely reported finding is that of ductal carcinoma in situ (DCIS) in males in association with gynecomastia. Only 2 cases have been reported in the literature [9,10], both in adults. Herein, we present the first case of DCIS in an adolescent with gynecomastia.

1. Case report

A 16-year-old adolescent Hispanic boy presented with a 1-year history of bilateral breast enlargement. On physical examination, he was found to have nearly symmetrical breast enlargement with a palpable, firm, well-defined, tender 7 × 5-cm subareolar disc of tissue on both sides associated with breast protrusion 4 cm above the skin surface (Fig. 1). Further examination revealed no abnormalities. Because of pain with contact sports, failure of resolution after a year, and the psychological burden posed on the patient by his peers, a bilateral subcutaneous mastectomy was performed.

Through a circumareolar incision, a mass of tissue measuring 8.5 × 5.6 × 3.4 cm (81.2 g) was removed from the right breast and another mass 6.5 × 5.1 × 3.4 cm (50.5 g) from the left breast. No discrete lesions, areas of nodularity, or calcifications were identified. The patient had uneventful healing of his wounds with good cosmetic results (Fig. 2).

* Corresponding author. Department of Surgery, Baystate Medical Center, 759 Chestnut St, Springfield, MA 01199.

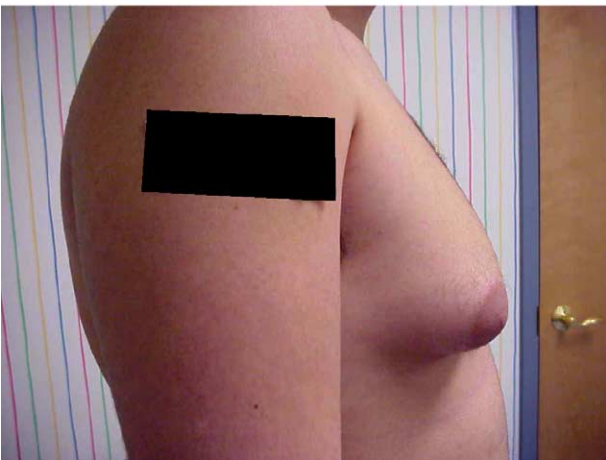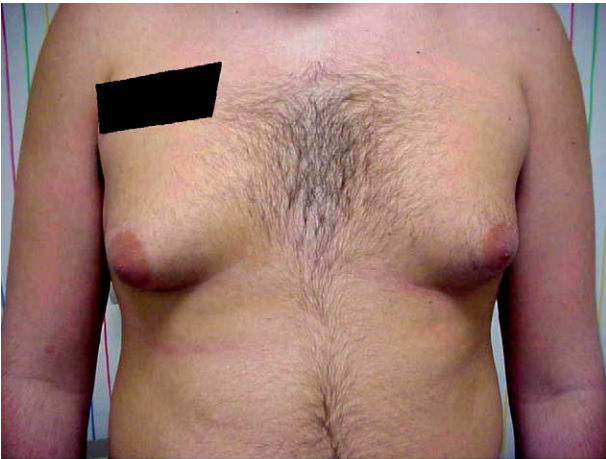


Fig. 1 Preoperative pictures showing moderate to severe symmetrical bilateral gynecomastia with breast protrusion 4 cm above the skin surface.

Histopathological examination identified a single focus of DCIS in the right breast, 2.5 mm in greatest dimension involving a single duct. The DCIS focus was subclassified

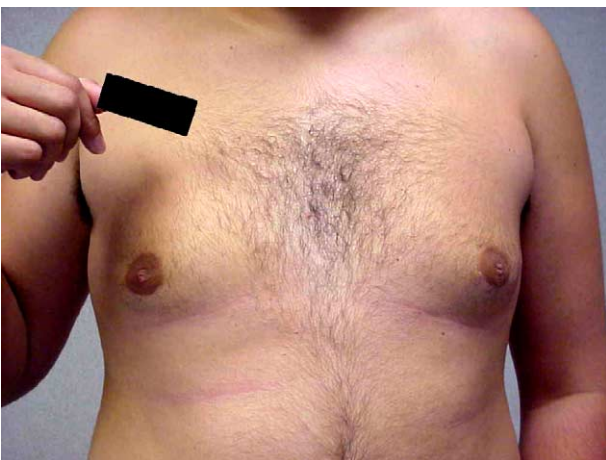


Fig. 2 Postoperative picture showing significant reduction of the size of both breasts. The circumareolar scar is unremarkable and the breasts have a smooth symmetrical contour.

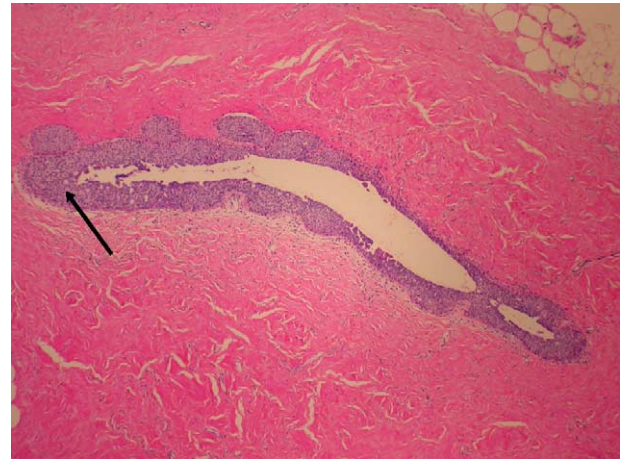


Fig. 3 Microscopic picture of the duct involved with DCIS. The whole duct is lined with several layers of atypical cells with clustering at one end (arrow) (H&E, original magnification $\times 40$).

as intermediate grade, cribriform type without comedo necrosis. The margins of resection were free of DCIS (>2 mm) in all directions. The lesion was assigned a Van Nuys Prognostic index (VNPI) of 5 (1 for size, 2 for grade, and 2 for margins) (Figs. 3 and 4). The remaining right breast, as well as the left breast tissue, showed evidence of gynecomastia overall of the fibrous type with widespread atypical ductal hyperplasia. The results of immunohistochemical staining demonstrated positivity for both estrogen and progesterone receptors in the DCIS focus as well as the surrounding breast tissue. A peripheral blood karyotype was normal ruling out Klinefelter's syndrome. The patient underwent bilateral completion total mastectomies with free nipple grafts. Reexcision histopathology revealed residual bilateral gynecomastia with atypical ductal hyperplasia, but no DCIS or infiltrating carcinoma.

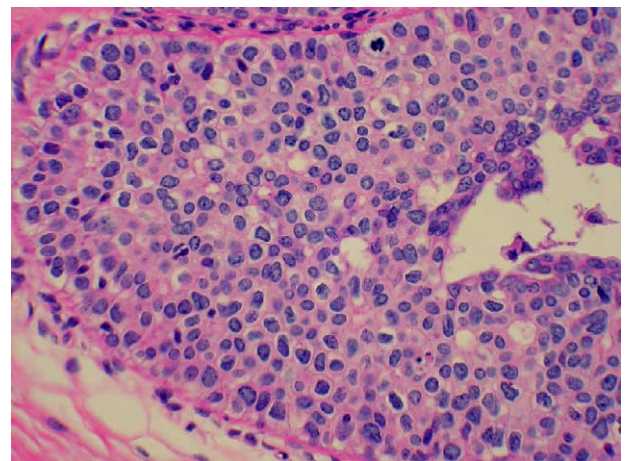


Fig. 4 The area of the duct shown in Fig. 3 with heaped-up neoplastic cells extending into the lumen and having a cribriform pattern. No comedo necrosis is identified (H&E, original magnification $\times 200$).

2. Discussion

Pubertal gynecomastia is considered by many to be a phase of normal development rather than a disease process [11]. In the majority of teenagers, no underlying etiology can be identified, and the condition usually regresses spontaneously in 1 to 2 years [12].

It is important to exclude the presence of malignancy in a patient with gynecomastia. Clinical examination is usually sufficient for this purpose [13,14]. The only disorder proven to be associated with an increased risk of breast cancer in men is Klinefelter's syndrome [15] characterized by a 47,XXY karyotype together with gynecomastia, testicular hypoplasia, and azoospermia [16]. Testicular examination is therefore essential in these cases, and, if abnormal, laboratory studies may be helpful (eg, serum LH/FSH, sperm count and a peripheral blood karyotype) [14]. Unless the patient presents with a unilateral, firm, irregular mass, bloody nipple discharge, or a clinical picture suspicious for Klinefelter's syndrome, a breast biopsy is unnecessary [11,17]. In the case described herein, both breasts were enlarged with no discrete masses, and there were no features suggestive of Klinefelter's syndrome, and, hence, a biopsy was not felt beneficial. The use of mammography to workup patients with gynecomastia is advised by a few authors [18,19] based on its ability to differentiate fat from glandular tissue and identify suspicious masses; however, this view is not held by many others [13,20] because of the small size and dense nature of the male breast tissue.

The majority of the time in patients with gynecomastia reassurance is all that is needed, especially when the breast diameter is less than 4 cm [11]. Correction of an identified hormonal abnormality or withholding an offending drug is sometimes sufficient. Several pharmacological agents have been tried with variable results including antiestrogens such as *clomiphene citrate* [21] and *tamoxifen* [22], as well as synthetic androgens such as *dihydrotestosterone heptanoate* [23] and *danazol* [24].

Surgery is recommended if the above measures fail to alleviate pain, psychological concerns, or the suspicion of a malignant process [13]. Subcutaneous mastectomy through a periareolar incision has been recommended [25]. Liposuction is another increasingly used modality. Patients with severe breast enlargement, excess skin, and protruding nipples according to Simon's classification [26] may require excision that includes the nipple, with or without additional liposuction [11]. Our patient had persistence of pain and discomfort after a year of follow-up and continued to experience psychological problems because of his body image. For these reasons, which may be regarded as mainly cosmetic, and in the presence of excess skin as well as gynecomastia of the mixed type, the decision was made to perform a bilateral subcutaneous mastectomy rather than a liposuction.

Findings on pathological examination of the excised breast tissue in cases of gynecomastia vary with the

temporal phase of the disease. Florid gynecomastia, over time, regresses to the intermediate rather than the fibrous phases [11,27]. All phases demonstrate increased number and cellularity of mammary ducts surrounded by a fibrous stroma with variable periductal cellularity, edema, and chronic inflammation [11]. In this case, a focus of DCIS and bilateral atypical ductal hyperplasia were also found. The association of DCIS and gynecomastia has been reported in the literature only twice, both in adult men, a 32-year-old and a 60-year-old [9,10].

Ductal carcinoma in situ in males is rare, accounting for about 7% of all male breast carcinomas [28]. Most of the literature on DCIS is derived from experience with the female variant of the disease. Pathologically, 5 architectural types of DCIS have been described in women [29-31]: comedo, cribriform, solid, micropapillary, and papillary. In males, all types have been described with the exception of the micropapillary pattern [32,33]. Because of its rarity in males, the disease is associated with a high risk of error in diagnosis, particularly when associated with gynecomastia. In these cases, focal squamous metaplasia [34] and extreme epithelial hyperplasia [35] may simulate DCIS.

The use of mammography in women has revolutionized the management of DCIS, leading to its detection in the subclinical stage in 85% of cases [36]. This, however, does not apply to men where most *denovo* DCIS cases present as a palpable mass (75%) or bloody nipple discharge (25%) [28]. In these patients, a tissue diagnosis is the first step unless DCIS is incidentally discovered, as in the reported case.

The management of male patients with DCIS has not been extensively studied, and no firm guidelines for treatment exist. The first major advance in management was the elimination of axillary lymph node dissection as this was uniformly negative for malignancy [28,32]. The management of the breast itself had been more controversial. Three options are available: lumpectomy, local excision followed by radiotherapy, and mastectomy. In males, lumpectomy with or without radiotherapy for DCIS has no real support in the literature and is considered unnecessary by several sources [28]. In addition, as the majority of these lesions are subareolar, nipple excision will be required [20]. Thus, most authorities recommend total mastectomy in males [28]. With this approach, the recurrence rate has thus far been 0% [20,37]. Radiotherapy, tamoxifen, or chemotherapy is not required in males after total mastectomy for DCIS [28]. Our patient underwent a completion total mastectomy with free nipple grafting. No recurrent lesions have been identified to date for 6 months' follow-up.

In women, 3 prognostic factors have been shown by multivariate analysis to determine the aggressiveness and, hence, the possibility of local recurrence of DCIS after breast conservation therapy [36,38,39]. These are lesion size, margin status, and histological grade (nuclear grade and presence or absence of comedo necrosis), with the histological grade being the most significant [40,41]. The

VNPI was based on these variables and assigned a score from 1 to 3 to each factor. For size, a score of 1 is given for tumors 15 mm or less, 2 for tumors 16 to 40 mm, and 3 for those 41 mm or more in diameter. For margins, a score of 1 is given for widely clear tumor-free margins of 10 mm or more, 2 for intermediate margins of 1 to 9 mm, and a score of 3 for margins less than 1 mm. For histological grade, a score of 3 is given for all high-grade lesions, 2 for non-high-grade lesions with comedo-type necrosis, and a score of 1 for non-high-grade lesions without comedo-type necrosis [42]. The total score thus ranges between 3 (most favorable) and 9 (least favorable) [36]. At the Breast Center (Van Nuys, Calif), patients with a score of 3 to 4 are offered local excision without radiotherapy. Those with scores 5 to 7 are offered local excision and radiotherapy as this was found to decrease the local recurrence rate by 14%. Patients with a score of 8 to 9 are offered lesionectomy and radiotherapy or mastectomy in face of the high recurrence rate even with the use of radiotherapy [36]. Whether the VNPI and its use in guiding treatment options apply also to DCIS in males has not been studied. Our patient had a VNPI of 5. Whether he would have benefited from only lumpectomy and radiotherapy or down scoring by reexcision, as would have been the case in a female with DCIS of the same score, is not known.

In conclusion, pubertal gynecomastia is a common problem in the adolescent male population. The majority of cases spontaneously regress and require no specific treatment. However, the surgeon should bear in mind the rare possibility of the breast harboring a malignant lesion, and, if clinically suspicious, a more aggressive workup, including an excisional biopsy, is required. In cases where DCIS is identified, total mastectomy appears to be the safest option, until further studies define the role of breast conservation therapy in males.

References

- [1] Courtiss EH. Gynecomastia: analysis of 159 patients and current recommendations for treatment. *Plast Reconstr Surg* 1987;79(5):740-50.
- [2] Fodor PB. Breast cancer in a patient with gynecomastia. *Plast Reconstr Surg* 1989;84(6):976-9.
- [3] Nydick M, Bustos J, Dale Jr JH, et al. Gynecomastia in adolescent boys. *JAMA* 1961;178(5):449-54.
- [4] Williams MJ. Gynecomastia: its incidence, recognition, and host characterization in 447 autopsy cases. *Am J Med* 1963;34:103.
- [5] Crichlow RW. Breast cancer in males. *Breast* 1976;2:12.
- [6] Crichlow RW. Carcinoma of the male breast. *Surg Gynecol Obstet* 1972;134:1011.
- [7] Heller U, Rosen P, Schattenfeld D, et al. Male breast cancer. *Ann Surg* 1978;188:60-5.
- [8] Azzopardi JG. Problems in breast pathology. Philadelphia (Pa): Saunders; 1979. p. 322-4.
- [9] Cole FM, Qizilbash AH. Carcinoma in situ of the male breast. *J Clin Pathol* 1979;32:1128.
- [10] Dershaw DD, Borgen PI, Deutch BM, et al. Mammographic findings in men with breast cancer. *AJR Am J Roentgenol* 1993;160:267-70.
- [11] Bland KI, Graves TA, Page DL. Gynecomastia. In: Bland KI, Copeland III EM, editors. *The breast: comprehensive management of benign and malignant diseases*. 2nd ed. Philadelphia (Pa): WB Saunders; 1998. p. 153-89.
- [12] Andrassy RJ. Benign breast lesions in children and adolescents. *Cancer Bull* 1988;40:33-5.
- [13] Carlson HE. Gynecomastia, current concepts. *N Engl J Med* 1980;303(14):795-9.
- [14] Wilkins L. The diagnosis and treatment of endocrine disorders in childhood and adolescence. 3rd ed. Springfield (Ill): Charles C Thomas; 1965. p. 207-8.
- [15] Scheike O, Visfeldt J, Peterson B. Male breast cancer: 3. Breast carcinoma in association with the Klinefelter syndrome. *Acta Pathol Microbiol Scand A* 1973;81:352-8.
- [16] Griffin JE, Wilson JD. Disorders of the testes and the male reproductive tract. In: Larsen PR, Kronenberg HM, Melmed S, editors. *Williams textbook of endocrinology*. 10th ed. Philadelphia (Pa): WB Saunders; 2003. p. 732-3.
- [17] Sullivan JJ, Magee JJ, Donald KJ. Secretory (juvenile) carcinoma of the breast. *Pathology* 1977;9:341-6.
- [18] Haagensen CD. Diseases of the breast. 2nd ed. Philadelphia (Pa): WB Saunders; 1971. p. 76-84.
- [19] Cooper RA, Gunter BA, Ramamurthy L. Mammography in men. *Radiology* 1994;191:651-6.
- [20] Wilhelm MC, Langenburg SE, Wanebo HJ. Cancer of the male breast. In: Bland KI, Copeland III EM, editors. *The breast: comprehensive management of benign and malignant diseases*. 2nd ed. Philadelphia (Pa): WB Saunders; 1998. p. 1416-20.
- [21] Stephanas AV, Burnet RB, Harding PE, et al. Clomiphene in the treatment of pubertal-adolescent gynecomastia: a preliminary report. *J Pediatr* 1977;90:651-3.
- [22] McDermott MT, Hofeldt FD, Kidd GS. Tamoxifen therapy for painful idiopathic gynecomastia. *South Med J* 1990;83:1283-5.
- [23] Eberle AJ, Sparrow JT, Keenan BS. Treatment of persistent pubertal gynecomastia with dihydrotestosterone heptanoate. *J Pediatr* 1986;109:144-9.
- [24] Buckle R. Danazol in the treatment of gynecomastia. *Drugs* 1980;19:356-61.
- [25] Webster JP. Mastectomy for gynecomastia through a semicircular intra-areolar incision. *Ann Surg* 1946;124:557-75.
- [26] Simon BE, Hoffman S, Khan S. Classification and surgical correction of gynecomastia. *Plast Reconstr Surg* 1973;51:48.
- [27] Bannayan GA, Hadju S. Gynecomastia, clinicopathologic study of 351 cases. *Am J Clin Pathol* 1972;57:432-7.
- [28] Camus MG, Joshi MG, Mackarem G, et al. Ductal carcinoma in situ of the male breast. *Cancer* 1994;74(4):1289-93.
- [29] Lagios MD, Margolin FR, Westdahl PR, et al. Mammographically detected duct carcinoma in situ: frequency of local recurrence following tylectomy and prognostic effect of nuclear grade on local recurrence. *Cancer* 1989;63:618-24.
- [30] Holland R, Hendriks JHCL, Verbeek ALM, et al. Extent, distribution, and mammographic/histological correlations of breast ductal carcinoma in situ. *Lancet* 1990;335:519-22.
- [31] Fisher ER, Sass R, Fisher B, et al. Pathologic findings from the National Surgical Adjuvant Breast Project (Protocol 6): I. Intraductal carcinoma (DCIS). *Cancer* 1986;57:197-208.
- [32] Heller KS, Rosen PP, Schottenfeld D, et al. Male breast cancer: a clinicopathologic study of 97 cases. *Ann Surg* 1978;188:60-5.
- [33] Johnson RL. The male breast and gynecomastia. In: Page DL, Anderson TJ, editors. *Diagnostic histopathology of the breast*. New York (NY): Churchill Livingstone; 1988. p. 30-42.
- [34] Gottfried MR. Extensive squamous metaplasia in gynecomastia. *Arch Pathol Lab Med* 1986;110:971-3.

- [35] Nielsen BB. Fibroadenomatoid hyperplasia of the male breast. *Am J Surg Pathol* 1990;14:774-7.
- [36] Silverstein MJ, Craig PH. Ductal carcinoma in situ: controversial issues. In: Bland KI, Copeland III EM, editors. *The breast: comprehensive management of benign and malignant diseases*. 2nd ed. Philadelphia (Pa): WB Saunders; 1998. p. 1044-71.
- [37] Frykberg ER, Masood S, Copeland III EM, et al. Ductal carcinoma in situ of the breast. *Surg Gynecol Obstet* 1993;177:425-40.
- [38] Schnitt SJ, Abner A, Gelman R, et al. The relationship between microscopic margins of resection and the risk of local recurrence in patients with breast cancer treated with breast-conserving surgery and radiation therapy. *Cancer* 1994;74:1746-51.
- [39] Lagios MD, Page DL. In situ carcinomas of the breast: ductal carcinoma in situ, Paget's disease, lobular carcinoma in situ. In: Bland KI, Copeland III EM, editors. *The breast: comprehensive management of benign and malignant diseases*. 2nd ed. Philadelphia (Pa): WB Saunders; 1998. p. 261-83.
- [40] Lagios MD. Ductal carcinoma in situ. *Controversies in diagnosis, biology and treatment*. *Breast J* 1995;1:67-78.
- [41] Silverstein MJ, Lagios MD, Craig PH, et al. A prognostic index for ductal carcinoma in situ of the breast. *Cancer* 1996;77:2267-74.
- [42] Silverstein MJ, Poller DN, Waisman JR. Prognostic classification of breast ductal carcinoma in situ. *Lancet* 1995;345:1154-7.