



The appendix sign: a radiographic marker for irreducible intussusception

Marion C.W. Henry^a, Christopher K. Breuer^{a,*}, David B. Tashjian^a, R. Lawrence Moss^a,
Milissa McKee^a, Robert Touloukian^a, T. Rob Goodman^b, Cindy Miller^b, Jamal Bokhari^b

^aDivision of Pediatric Surgery, Yale University School of Medicine, New Haven, CT 06520, USA

^bDivision of Pediatric Radiology, Yale University School of Medicine, New Haven, CT 06520, USA

Index words:

Intussusception;
Radiography;
Surgery;
Sensitivity;
Specificity

Abstract

Purpose: Radiographic reduction (hydrostatic or pneumatic) of intussusception has become the standard of care in the pediatric population with success rates of more than 80%. Identification of those patients who are likely to fail nonoperative management could lead to earlier operation, a reduction in radiation exposure, and a decreased risk for complications after repeated attempts at enema reduction. During successful radiographic reduction, the small bowel is almost always visualized before the appendix. Visualization of the appendix before visualization of the small bowel during a successful reduction of an intussusception is a rare event. We report a new radiographic sign that we have termed the *appendix sign* (radiographic visualization of the appendix without reflux of air or contrast into the small intestine), which we hypothesize may have association with failure of nonoperative management.

Method: We performed a retrospective review of the last 12 years of irreducible intussusception. The associated studies were then reviewed to examine the incidence, sensitivity, and specificity of this radiographic finding.

Results: Ninety-one cases of intussusception were identified and had films available for review. Seventy-seven (76%) of the studies included the appropriate image. The appendix sign was visualized in 14 studies for an incidence of 18%. Of 14 patients, 10 failed enema reduction (positive predictive value, 71%). The sensitivity of the appendix sign is 43%. The specificity of the sign is 93%.

Conclusions: Our experience suggests that the presence of an appendix sign is associated with failing enema reduction of an intussusception and may be useful as a marker for determining the end point for further attempts at radiographic reduction.

© 2006 Published by Elsevier Inc.

Radiographic pneumatic reduction of intussusception has become widely accepted within the pediatric surgery and radiology community. Variable success rates of more than

80% are reported [1]. Patients who fail initial radiographic reduction often undergo laparotomy, where either manual reduction or bowel resection is performed. In some cases, the intussusception has spontaneously reduced at the time of surgery. Repeat enema has also been attempted with some success [2]. Identification of patients who are likely to fail radiographic reduction can lead to more expedient treatment with potentially fewer complications for this subset of

* Corresponding author. FMB 132, PO Box 208062, New Haven, Connecticut 06520-8062, USA. Tel.: +1 203 785 2701.

E-mail address: christopher.breuer@yale.edu (C.K. Breuer).

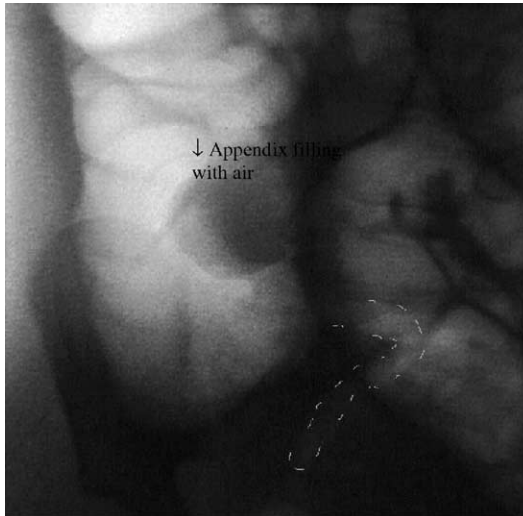


Fig. 1 The appendix sign.

patients. During successful reduction, air is visualized in the small bowel before the appendix. When air is seen in the appendix first, a high likelihood of failure of pneumatic reduction exists. We report on our series of patients with this radiographic finding called the *appendix sign*.

1. Methods

A retrospective review of cases of intussusception between 1992 and 2004 was performed. Patients with intussusception and attempts at radiographic pneumatic reduction were identified. The radiographic studies of these patients were reviewed by 2 separate radiologists to examine the incidence of a new radiographic finding, the appendix sign. This sign consists of visualization of the appendix without reflux of air

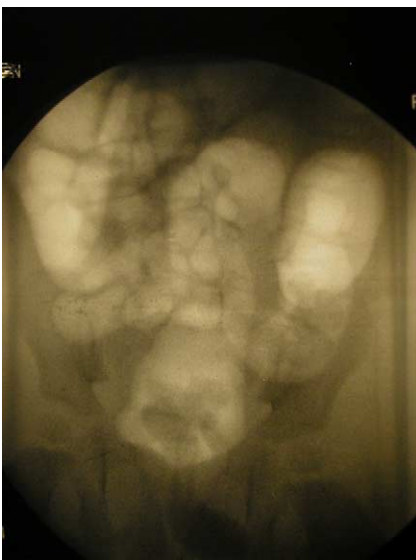


Fig. 2 Normal contrast enema showing successful reduction and no visualization of the appendix.

Table 1 Visualization of the appendix sign and result of reduction

	Failed reduction	Successful reduction
Appendix sign visualized	10	4
No appendix sign visualized	13	50

or contrast into the small intestine (Figs. 1 and 2). Institutional review approval was received for this study (Yale human investigation committee [HIC] 27180).

2. Results

Ninety-one cases of intussusception were identified and had films available for review. Seventy-seven (76%) of the studies included the appropriate image. Results are summarized in Table 1. The appendix sign was visualized in 14 studies for an incidence of 18%. Of 14 patients, 10 failed enema reduction (positive predictive value, 71%). The sensitivity of the appendix sign is 43%. The specificity of the sign is 93%.

3. Discussion

Radiographic reduction of intussusception has become the standard of care in the pediatric population with success rates of more than 80% [1,3]. Identification of those patients who are likely to fail nonoperative management could lead to earlier operation, a reduction in radiation exposure, and a decreased risk for complications after repeated attempts at enema reduction.

Enema reduction poses a risk for intestinal perforation. Perforation rates appear to range, with reported rates varying from 0% to 6% for pneumatic reduction under fluoroscopy, although only a very few series report rates greater than 1% [1]. Some perforations are suspected to have been present before attempted enema reduction, with a lack of free air because of the intussusciptions preventing the air to escape into the peritoneal cavity [1]. However, the actual incidence of these types of perforations is difficult to determine. Risk factors for perforation during attempts at enema reduction appear to be younger than 6 months, those presenting with a longer duration of symptoms (>36 hours) [1], improper technique with elevated pressures or pressures that were changed too rapidly [1], or an inexperienced operator.

Success rates with pneumatic reduction are reported to be more than 80%, and some reports have been as high as 95% [1,4,5]. However, to achieve such high rates of reduction, often repeated attempts at reduction are required. Although repeated attempts can be done successfully and safely, they are not without risks. Prolonged or repeated attempts at enema reduction can lead to swollen or gangrenous bowel requiring small bowel resection at the time of surgical

reduction. Bowel perforation has also been reported in delayed repeated reductions [6].

Prolonged or repeated attempts at reduction lead to increased radiation exposure for the patient as well. In one study, children with irreducible intussusception had an average radiation exposure time 3 times that of those with reducible intussusceptions [4]. Furthermore, screening times of 15 and 30 minutes were associated with radiation exposure, leading to respective risks for fatal cancer induction of about 1 in 2000 and 1 in 1000 [4]. Thus, preventing prolonged radiation exposures by identifying children likely to fail enema reduction can reduce these risks as well.

During successful radiographic reduction, the small bowel is almost always visualized before the appendix. Visualization of the appendix before visualization of the small bowel during a successful reduction of an intussusception is a rare event. In 54 cases of successfully reduced intussusception, we visualized the appendix only 4 times (7%).

In our series of patients with irreducible intussusception leading to laparotomy and small bowel resection, the appendix sign was present in 7 (78%) of 9 of cases. In all cases of intussusception, there was a high specificity and relatively high positive predictive value of this sign. These

results suggest, therefore, that when this sign is visualized, there is a strong likelihood of failing radiographic reduction. However, the low sensitivity shows that not visualizing the appendix sign does not rule out failing reduction. Based on these findings, visualization of the appendix sign may warrant stopping attempts at radiographic reduction and proceeding to operative management.

References

- [1] Daneman A, Navarro OM. Intussusception. *Pediatr Radiol* 2004;34:97-108.
- [2] Sandler AD, Ein SH, Connolly B, et al. Unsuccessful air-enema reduction of intussusception: is a second attempt worthwhile? *Pediatr Surg Int* 1999;15:214-6.
- [3] Merten DF. Practical approaches to pediatric gastrointestinal radiology. *Radiol Clin North Am* 1993;3:1395-404.
- [4] Heenan SD, Kyriou J, Fitzgerald M, et al. Effective dose at pneumatic reduction of paediatric intussusception. *Clini Radiol* 2000;55:811-6.
- [5] Guo JZ, Ma XY, Zhou QH. Results of air pressure enema reduction of intussusception: 6396 cases in 13 years. *J Pediatr Surg* 1986;21:1201-3.
- [6] Navarro OM, Daneman A, Chae A. Intussusception: the use of delayed, repeated reduction attempts and the management of intussusceptions due to pathologic lead points in pediatric patients. *AJR Am J Roentgenol* 2004;182:1169-76.